

Differentiation of Malignant and Benign Masses on Mammograms Using Radial Local Ternary Pattern

Chisako Muramatsu¹, Min Zhang¹, Takeshi Hara¹, Tokiko Endo^{2,3}, and Hiroshi Fujita¹

¹ Department of Intelligent Image Information, Gifu University, Gifu, Japan
{chisa,min,hara,fujita}@fjt.info.gifu-u.ac.jp

² Department of Radiology, Nagoya Medical Center, Nagoya, Japan

³ Department of Radiology, Higashi Nagoya National Hospital, Nagoya, Japan
endot@nnh.hosp.go.jp

Abstract. Texture information of breast masses may be useful in differentiating malignant from benign masses on digital mammograms. Our previous mass classification scheme relied on shape and margin features based on manual contours of masses. In this study, we investigated the texture features that were determined in regions automatically selected from square regions of interest (ROIs) including masses. As a preliminary investigation, 149 ROIs including 91 malignant and 58 benign masses were used for evaluation by a leave-one-out cross validation. The local ternary pattern and local variance were determined in sub regions with the high contrast and a core region. Using an artificial neural network, the classification performance of 0.848 in terms of the area under the receiver operating characteristic curve was obtained.

Keywords: Breast masses, mammograms, computer-aided diagnosis, classification, texture feature, local ternary pattern.

1 Introduction

Distinction between benign and malignant lesions on mammograms can be difficult. We have been investigating a computerized image analysis method for assisting radiologists' diagnosis of breast images. In our previous studies [1-4], determination of similarity measures was investigated for retrieval of reference images that are similar to a new case to be diagnosed. Some characteristics of breast masses that radiologists may consider during the mammography reading include the mass shapes, e.g., round or irregular, the margin characteristics, e.g., circumscribed or spiculated, and the density, whether it is higher than that of the surrounding fibroglandular tissue or iso-dense. The image features determined for the similarity measures included such features characterizing the shape, density and margin. However, in our previous methods, it has been found that the shape and margin features are predominantly useful, and the density features, such as the contrast and standard deviation in pixel values, were considered not very useful. This fact indicates that the characteristics that radiologists find for diagnosis might not be fully reflected in our previous features. Other features such as textural features may represent mass density characteristic and be useful in the distinction between benign and malignant masses.

In addition, the shape and margin features were determined on the basis of the manual outline of a mass in our previous study. However, obtaining the detailed contour of a mass from practitioners is not practical, and automatic delineation is not easy. In this study, we investigated new textural features, namely, modified local ternary patterns (LTP) [5], determined in regions automatically selected from a square region of interest (ROI) including masses for classification between benign and malignant masses.

2 Materials and Methods

2.1 Database

Digital mammograms used in this study were obtained at Nagoya Medical Center, Nagoya, Japan, with either the phase contrast mammography (PCM) units (Mermaid/Pureview, Konica Minolta, Inc.) or computer radiography (CR) system (Mammomat 3000, Siemens and C-Plate, Konica Minolta). This study was approved by the institutional review board. The pixel sizes of the images are 25 (PCM) and 43.75 (CR) microns and the gray level is 12 bits. For image processing, the pixel size and gray scale were unified to 50 microns and 10 bits by linear interpolation. All the mammograms were retrospectively reviewed by one of two radiologists with the diagnostic report and the corresponding ultrasonography images, if available, and the square ROIs including masses were obtained. In this study, 149 ROIs, including 91 malignant and 58 benign masses were used. The malignant masses were confirmed by biopsy or surgery, while benign masses were diagnosed by biopsy or follow-ups with other image modalities. The average and standard deviation of mass diameters are 35 ± 18 mm, and the size of ROIs ranged from 250 x 250 to 1758 x 1758 pixels.

2.2 Methods

Modified Local Ternary Pattern. Local ternary pattern (LTP) [5] is a variant of the local binary pattern (LBP) [6], which is a sequence of binarized information of the pixels surrounding the pixel of interest. Assuming there is a slope or an edge around the pixel of interest, such as in Fig. 1(a), the surrounding pixels are compared with the pixel of interest and binarized to have 1 or 0 depending on the superiority of the pixel value, as in Fig. 1(b). LBP takes the parameters of R and P , which are the radius and the number, respectively, of the surrounding pixels for comparison and 1 and 8, respectively, for the above example. Starting arbitrarily from the pixel on the right in clockwise, the pattern for this pixel of interest will be 00011110. For an ROI, the histogram of patterns is built and used for the subsequent process of classification.

Because actual images include some noise, LTP was proposed to include a margin on the threshold, and the output became three values as -1, 0, and 1, corresponding to the surrounding pixel values smaller than that of the pixel of interest minus a threshold, within the threshold, and larger than that plus threshold, respectively. If we set the threshold to 3 in the same example above, the output becomes as in Fig. 1(c). These values can be separated by the positive and negative values to two binary

determined at each pixel in these sub-ROIs and the combined histogram was obtained for the case.

By selecting the sub-ROIs with the high contrast, the regions around the margin of a mass are likely selected as in Fig. 2. However, the texture characteristic of the core region is also important. In addition to the high contrast sub-ROIs, an LTP histogram for a core sub-ROI of 50×50 pixels placed in the center of the square ROI was also obtained. For the core ROI, the rotation invariant LTP was determined. In this study, the threshold for LTP was set to 5 and the R and P parameters were set to 2 and 8, respectively. As the supplemental information, the histograms of variances in pixel values were obtained in both selected sub-ROIs and the core sub-ROI [6]. The variance for each pixel was determined in the 7×7 pixel area, and the number of bins was set to 10. Therefore, the total number of the features (concatenated histogram bins) was 89.

For classification of benign and malignant ROIs, an artificial neural network (ANN) was used. The feed forward ANN with a backpropagation algorithm was employed. The ANN was trained and evaluated by a leave-one-out cross validation method. Because of the large number of features relative to the number of training cases, the feature reduction was performed by a forward feature selection. The result was evaluated by the area under the receiver operating characteristic curve (AUC). The parameters of ANN were selected experimentally on the basis of the AUC.




Fig. 2. Locations of selected sub-ROIs specified by small squares. (a) A malignant ROI of 392×392 pixels, and (b) a benign ROI of 276×276 pixels.

3 Results

With the forward feature selection, 6 features were selected. Four were from the radial LTP in the selected sub-ROIs and two were from the rotation invariant LTP in the core ROI. No feature was selected from the variance histograms in this study. Figure 3 shows the change in classification performance in terms of AUC with the number of features selected. For each number of features, at least 3 different numbers of hidden units were tested. The selected numbers of hidden units and training iterations were 5 and 200, respectively. The classification performance was 0.848 in terms of AUC.

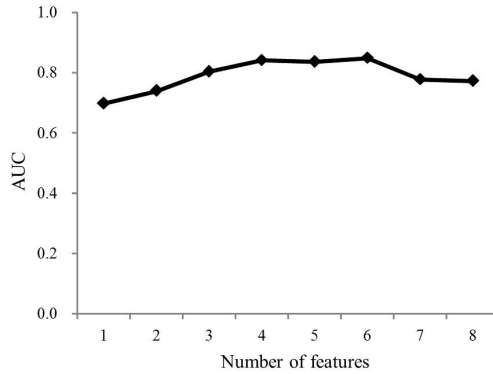


Fig. 3. Change in AUC with the number of features selected

4 Discussion

For evaluation of the effectiveness of the radial LTP to the regular LTP and the effects of image size and grayscale reductions, F -statistics were determined. For these evaluations, the scores obtained by the linear discriminant analysis (LDA) using all features were employed. The F -statistic in this study is defined as the ratio of the inter-class and intra-class variances by

$$F = \frac{S_b}{S_w} = \frac{n_1 n_2}{n} \cdot \frac{(m_1 - m_2)^2}{n_1 \sigma_1^2 + n_2 \sigma_2^2},$$

where n is the number of cases and m and σ are the mean and the standard deviation, respectively, of LDA scores for each class.

The F -statistic of the proposed method with the reduced image size and grayscale was 1.73, whereas those with original size and grayscale were 1.56 and 1.39, respectively. These results indicate that the effects of the image size and grayscale reductions are small. The F -statistic of the regular LTP was 1.12, indicating the effectiveness of the radial LTP.

In this study, descriptive sub-ROIs were selected automatically on the basis of the histogram of pixel values. In the previous studies for classification of textural patterns, LBP or LTP was determined at all pixels within the images to be classified. However, for the classification of lesions like breast masses, unrelated information could be included by using all pixels which might affect the classification. On the other hand, by automatically selecting sub-ROIs, some were placed at regions unrelated to the mass, such as at the breast margin, as shown in Fig. 4. Sampling method should be investigated further in the future.

For reducing the number of features, a forward selection method was employed in this study. Liao et al. [7] proposed the selection of dominant patterns for reduction of the numbers of bins. Nanni et al. [8] selected the useful patterns on the basis of the variances of the training cases. The number of features was further reduced by the

principal component analysis. They applied the method for classification of benign and malignant masses and obtained the high classification performance. Although the performances of their method and our proposed method cannot be directly compared because of the different databases used, it is possible that some useful information may have been lost by selecting a small number of features. The feature reduction method must be investigated in the future study.

In this study, we investigated the usefulness of texture features, i.e., modified LTP, for classification between benign and malignant masses on mammograms. The LTP was determined in sub-ROIs that were automatically selected from a square ROI including a mass so that no precise segmentation of the mass was required. As a preliminary investigation, the classification performance was relatively well using only texture features without using contour information.

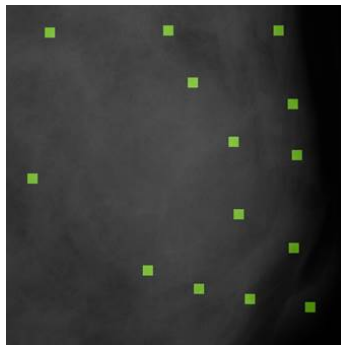


Fig. 4. Selected sub-ROIs at the breast margin

Acknowledgment. This study was partly supported by the Grants-in-Aid for Scientific Research for Young Scientists (No. 21791179) by Japan Society for the Promotion of Science and by a Grant-in-Aid for Scientific Research on Innovative Areas (No. 21103004), MEXT, Japan. Authors are grateful to Mikinao Oiwa, MD, and Misaki Shiraiwa, MD, for their contribution in this study.

References

1. Muramatsu, C., Li, Q., Schmidt, R.A., Shiraishi, J., Doi, K.: Determination of similarity measures for pairs of mass lesions on mammograms by use of BI-RADS lesion descriptors and image features. *Acad. Radiol.* 16, 443–449 (2009)
2. Muramatsu, C., Nishimura, K., Oiwa, M., Shiraiwa, M., Endo, T., Doi, K., Fujita, H.: Correspondence among subjective and objective similarities and pathologic types of breast masses on digital mammography. In: Maidment, A.D.A., Bakic, P.R., Gavenonis, S. (eds.) *IWDM 2012. LNCS*, vol. 7361, pp. 450–457. Springer, Heidelberg (2012)
3. Muramatsu, C., Nishimura, K., Endo, T., Oiwa, M., Shiraiwa, M., Doi, K., Fujita, H.: Representation of lesion similarity by use of multidimensional scaling for breast masses on mammograms. *J. Digit. Imaging.* 26, 740–747 (2013)

4. Nishimura, K., Muramatsu, C., Oiwa, M., Shiraiwa, M., Endo, T., Doi, K., Fujita, H.: Psychophysical similarity measure based on multi-dimensional scaling for retrieval of similar images of breast masses on mammograms. In: Novak, C.L., Aylward, S. (eds.) Proc. of SPIE Med. Imaging, vol. 8670, pp. 86701R1–R6 (2013)
5. Tan, X., Triggs, B.: Enhanced local texture feature sets for face recognition under difficult lighting conditions. *IEEE Trans. Image Processing* 19, 1635–1650 (2009)
6. Ojala, T., Pietikainen, M., Maenpaa, T.: Multiresolution gray-scale and rotation invariant texture classification with local binary patterns. *IEEE Trans. Pattern Anal. Mach. Intel.* 24, 971–987 (2002)
7. Liao, S., Law, M.W.K., Chung, A.C.S.: Dominant local binary patterns for texture classification. *IEEE Trans. Image Processing* 18, 1107–1118 (2009)
8. Nanni, L., Brahnam, S., Lumini, A.: A very high performing system to discriminate tissues in mammograms as benign and malignant. *Expert Systems with Applications* 39, 1968–1971 (2012)